



ISSN NO. 2320-5407

Journal homepage: <http://www.journalijar.com>

INTERNATIONAL JOURNAL
OF ADVANCED RESEARCH

RESEARCH ARTICLE

The biochemical effects of bee pollen suspension on prostatitis induced experimentally in rats.

Afaf D. Abd El-Magied¹; Mahmoud E. A. Abou-El-Roos²; Abd El-Haleem H. El-Kasapy³&* and M. A. Yuonis¹.

1. Department of Biochemistry, Faculty of Veterinary Medicine (Moshtohor), Banha University.

2. Department of Theriogenology, Faculty of Veterinary Medicine (Moshtohor), Banha University.

3. Department of Surgery, Anesthesiology and Radiology, Faculty of Veterinary Medicine (Moshtohor), Banha University.

Manuscript Info

Manuscript History:

Received: 18 August 2015

Final Accepted: 22 September 2015

Published Online: October 2015

Key words:

Castration, Prostatitis, Rats, bee pollen

*Corresponding Author

Abd El-Haleem H. El-Kasapy

Abstract

Prostatitis was induced in adult male Albino rats weighting 180-240 gm by castration under kitamine / xylazine anesthesia, and then Estradiol 0.25 mg/2ml/kg were subcutaneously injected into the back of rats for 30 days. Rats divided into four groups, sham-op group, model group, prophylaxis group, and treatment group. The biochemical effects of bee pollen suspension with a dose of (1250 mg/kg b.w.) have been studied through estimation of Testosterone, Estradiol, Interleukin 8, Prostaglandin E₂, and Immunoglobulin A concentrations in serum, also Malonaldehyde, Nitric Oxide, Reduced Glutathione concentrations, as well as Glutathione Peroxidase, Superoxide Dismutase, and Catalase activities in prostate tissues were measured each 15 days for two months. Results showed that, bee pollen suspension improved prostatitis conditions as inflammation, oxidative process and immunity which may be reflect on cure symptoms.

Copy Right, IJAR, 2015.. All rights reserved

INTRODUCTION

Prostatitis syndromes have been classified by the National Institute of Health in four categories, acute bacterial prostatitis (Categories I), chronic bacterial prostatitis (Categories II), chronic pelvic pain syndrome (CPPS, category III) is divided into CPPS-inflammatory (category IIIA) and CPPS non-inflammatory (category IIIB), and finally asymptomatic inflammatory prostatitis (category IV) (Motrich et. al, 2007). The patients symptoms usually present with protracted pelvic pain, perineal discomfort and significant lower urinary tract symptoms which has a significant impact on quality of life (Nickel et. al, 1990, and Shoskes 2002). The worldwide incidence of prostatitis has been estimated to be 3–16% of men, 90-95% of them suffer from Chronic prostatitis/chronic pelvic pain syndrome (CP/CPPS, NIH category III) (Hong-Jie et al, 2002, Kim et. al, 2009, Akdere et. al, 2015, and Motrich et. al, 2007). One important modulating factor in the development of prostatitis may be sex hormones, which have especially been linked to the autoimmune process. Chronic inflammation continuously produces inducible cyclooxygenase (COX-2) that increases the production of prostaglandin- E₂ (PGE₂) and reduces the E-c adherin protein. Chronic inflammation also produces free radicals as various reactive oxygen species (ROS) (Elberry et. al, 2011, and Yun Seok Jung et. al, 2014). When the humoral response was studied in CP/CPPS patients, increased levels of total IgA and IgG in the EPS and prostate tissue with unknown micro-organism specificity were detected (Motrich et. al, 2007). Pollens founded in two groups of, one group is made by honeybees and the other is directly collected from the flower of plants (Maruyama, 2010). Clinically the pollen extract has resulted in a reduction of pathologically increased white cell counts in prostatic secretions in patients with chronic Non-bacterial prostatitis, with a concomitant decrease in dysuria and discomfort or pain in the inguinal, perineal, or genital area. The therapeutic effectiveness of the pollen extract could be the result of an intra-prostatic inhibition of both the prostaglandin and

leukotriene biosynthesis and a subsequent anti-edematous and anti-leukotactic effect (Solujic et. al, 2008). Bee-collected pollen extracts show considerable antiradical activity PI: 35% inhibition which is significantly increased in the pollen extracts PI: 39-53% inhibition (Kroyer and Hegedus 2001).

MATERIALS AND METHODS

Animals:

Adult male Albino rats weighting 180-240 gm are housed in a climatized environment. Food and water supplied ad libitum. The 60 rats are castrated under kitamine / xylazine anesthesia, and then Estradiol 0.25 mg/ 2ml/kg diluted by sesame oil, as an inducer for prostatitis, were subcutaneously injected into the back of rats for 30 days from day 7 after castration. The remaining 20 rats were used as sham-op control, (Matsumoto et. al, 2013; Zhang et. al, 2010; Marinese et. al, 2003; Asakawa et. al, 2001; Kamijo et. al, 2001; Hanamoto et. al, 1998; Seethalakshmi et. al, 1996; and Naslund et. al, 1988).

Castration procedures:

Orchidectomy was performed aseptically, under kitamine (50 mg/kg) and xylazine (12 mg/kg) anesthesia, by the midscrotal incision then ligation of the spermatic cord and vessels, Remove testes and epididymides, push back the remaining stump through the inguinal canal into the abdominal cavity, scrotal sac was closed by sutures (Elberry et. al. 2011, and Sandford et. al. 1984).

grouping

Animal divided into, group I contains 20 rats as sham-op control (no castration , no treatment), group II contains 20 rats as a prostatitis model, no treatment, group III contains 20 castrated rats and injected s.c estradiol for 30 days and protected with Bee Pollen Suspension 1250 mg/kg as prophylaxis from the first day of estradiol injection followed by another 30 days, group IV contains 20 castrated rats and injected s.c estradiol for 30 days followed by treatment with Bee Pollen Suspension 1250 mg/kg for another 30 days .The rats were sacrificed on the day following the final administration at intervals 15, 30, 45, and 60 days from the first s.c. injection . The prostate was extirpated and cut into two parts. The first part fixated in 10% neutral buffered formalin and cut into coronal blocks. The tissue samples were dehydrated and embedded in paraffin. Sections (3-4 mm thickness) were stained with Hemotoxyline-Eosin (H&E), the specimens were evaluated histopathologically (Kamijo et. al, 2001) .The second part was freezed until estimation of Prooxidant and antioxidant parameters in prostate tissues. The blood samples were collected from the medial canthus of the rat eye at early morning after overnight fasting according to Wolford et. al, (1986).

Methods:-

Measurement of parameters in rat serum:

Testosterone, Estradiol, IL-8 , PGE2, IgA concentrations were estimated in rat serum by commercial ELISA kit from MyBioSource, Inc. catalog No.MBS702057, MBS702057 ,MBS263466 ,MBS2505616 ,MBS262150 , MBS2500774 respectively .

Determination of Prooxidant and antioxidant parameters in prostate tissues:-

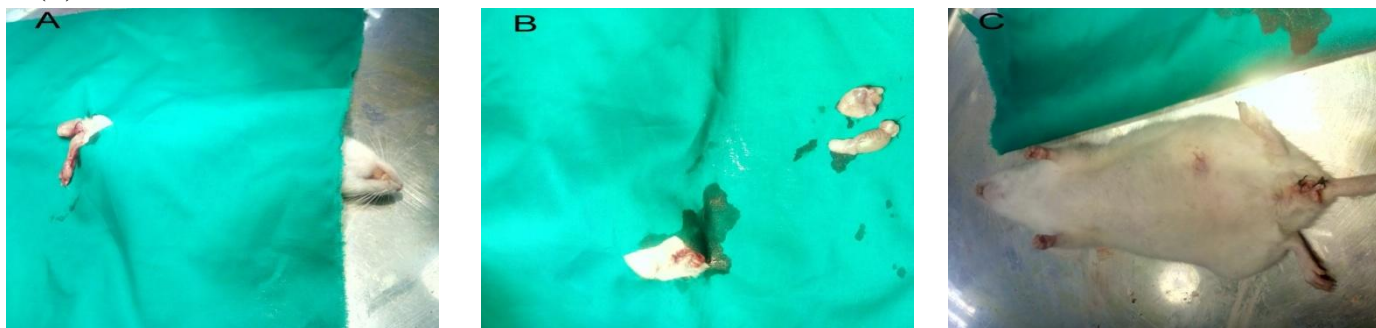
Prostate tissues L-Malonodialdehyde (MDA), Nitric oxide (NO) and reduced glutathione (GSH) concentrations were determined according to the method adopted by Esterbauer et. al. (1982), method of Montgomery and Dymock (1961), and method of Beutler et. al, (1963) respectively. While Glutathione peroxidase (GPx), Superoxide Dismutase (SOD), Catalase activities (CAT) were determined according to the method described by Paglia and Valentine (1967), method of Nishikimi et al., (1972), and method of Sinha, (1972) respectively.

Statistical analysis:

The Statistical analysis was carried out using ANOVA with two factors under significance level of 0.05 for the whole results using SPSS (ver. 22). Data were treated as complete randomization design according to Steel et al. (1997). Multiple comparisons were carried out applying LSD.

RESULTS

Figure (1) Rat castration procedures: (A) rat under anesthesia before testis removal, (B) after testis removal, (C) rat after scrotal sutures.



Changes in serum testosterone concentration:

The results in figure (2) showed that, the testosterone concentration was dramatically dropped in the three castrated rat groups (model, prophylaxis, and treatment) compared with control group. On the other hand there was a gradually decreasing in serum testosterone concentration with time in the three groups mentioned.

Changes in serum estradiol concentration:

The results in figure (3) showed that, the estradiol concentration was significantly increasing in the three castrated rat groups (model, prophylaxis, and treatment) compared with control group. Through the first 30 days there were a gradually increasing in serum estradiol concentration with time in the three group mentioned, then the last 30 days there were a gradually decreasing in serum estradiol concentration in these groups while the control group remained with almost no alteration through the whole period (60 days).

Changes in serum Interleukin 8 concentration:

The results in figure (4) revealed a significant elevation in IL-8 concentration in three groups (model, prophylaxis, and treatment) compared with control group after 15 days from starting point followed by a gradual decrease in IL-8 concentration for prophylaxis group and delayed in treatment group after 30 days while model group was still significantly high IL-8 concentration at the end of trail after 60 days.

Changes in serum PGE2 concentration:

As the results obtained with IL-8, the results in figure (5) showed a significant elevation in PGE2 concentration in three groups (model, prophylaxis, and treatment) compared with control group after 15 days from starting point followed by a gradual decrease in PGE2 concentration for prophylaxis group and delayed in treatment group after 30 days while model group was still significantly high PGE2 concentration at the end of trail after 60 days.

Changes in serum Immunoglobulin A concentration:

The results in figure (6) illustrated that, through the first 30 days a significant decrease in IgA concentration in the three groups (model, prophylaxis, and treatment) compared with control group, on contrast through the last 30 days, there are a significant increase in IgA concentration in the three mentioned groups compared with the initial state at 15 days. Rapid restore normal level was in prophylaxis group followed by treatment group.

Prooxidant and antioxidant status in prostate tissues:

The changes in prooxidant MDA and NO concentrations are illustrated in figures (7), (8) respectively. MDA concentration was extremely increased in the three groups (model, prophylaxis, and treatment) compared with control group after 15 days from starting point followed by a gradual decrease in MDA concentration for prophylaxis group until reached the normal level as control group after 60 days while this action is delayed in treatment group after 30 days, on contrast, model group is still extremely high MDA concentration at the end of trail after 60 days. NO concentrations resemble the data obtained with MDA conc except the rates of improvement is slow for prophylaxis, and treatment groups compared with the same groups in MDA results. The changes in antioxidant GSH concentration, GSHPx, SOD, and CAT activities illustrated in figures (9), (10), (11), (12) respectively. A significant decrease in the antioxidant in the three groups (model, prophylaxis, and treatment) compared with control group after 15 days from starting point followed by a gradual increase antioxidant effects for prophylaxis group and delayed in treatment group after 30 days while model group was stilling significantly low antioxidant effects at 60 days .The most sensitive antioxidant parameter is GSH conc which is began to improvement through the first 15 days and reached the normal level after 60 days in prophylaxis group .

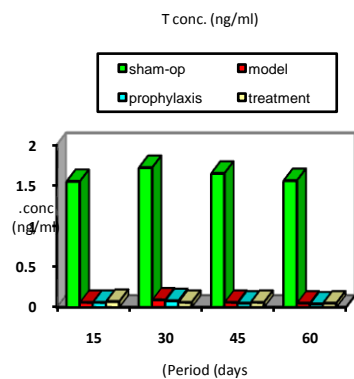


Fig. (2) Changes in serum testosterone

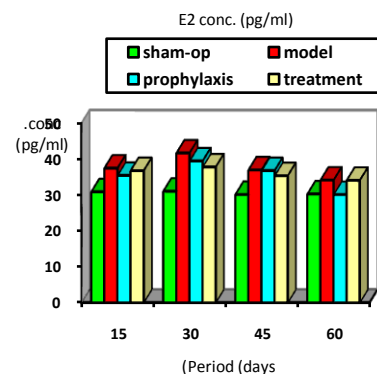


Fig. (3) Changes in serum estradiol

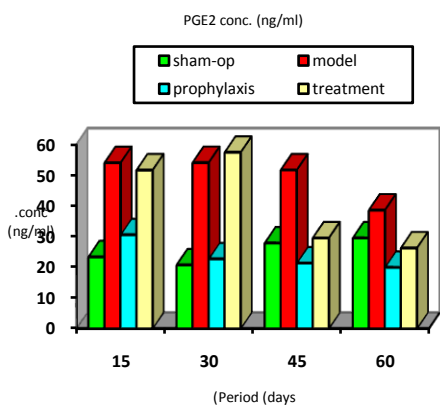


Fig. (4) Changes in serum PGE2

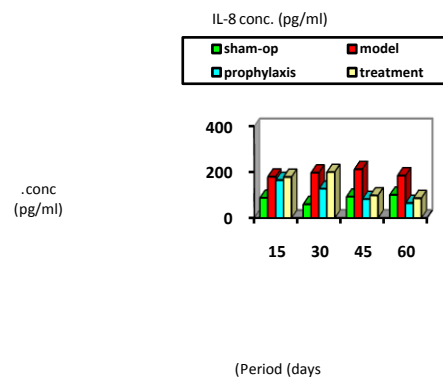


Fig. (5) Changes in serum IL-8

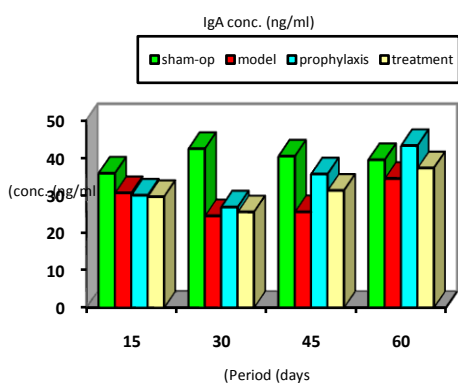


Fig. (6) Changes in serum IGA

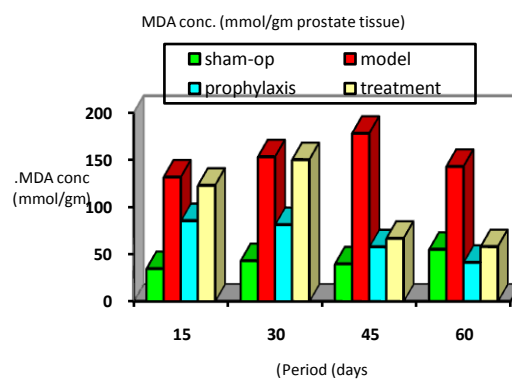


Fig. (7) Changes in tissue MDA

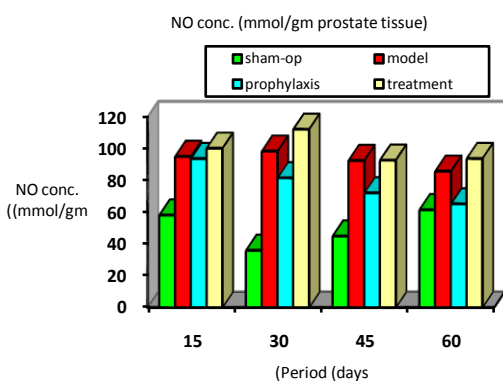


Fig (8) changes in tissues NO

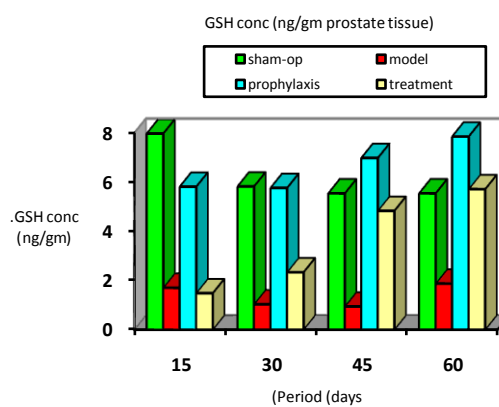


Fig. (9) Changes in tissue GSH

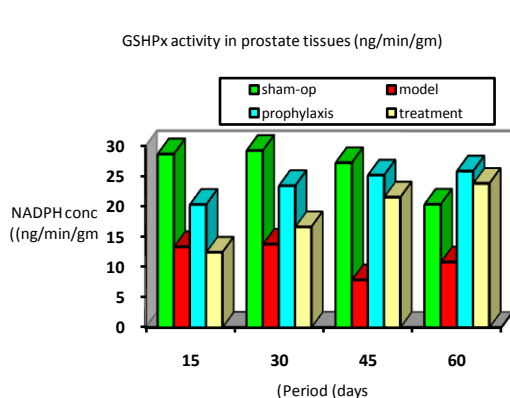


Fig. (10) Changes in tissue GSHPx

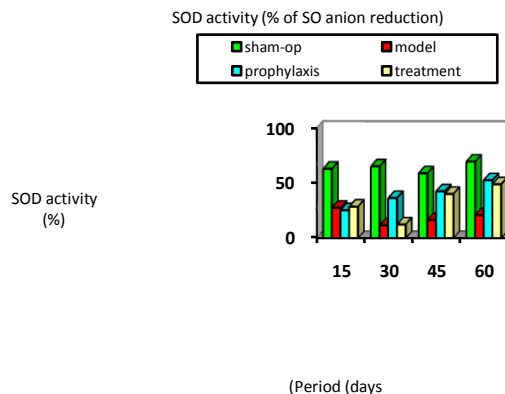


Fig. (11) Changes in tissue SOD

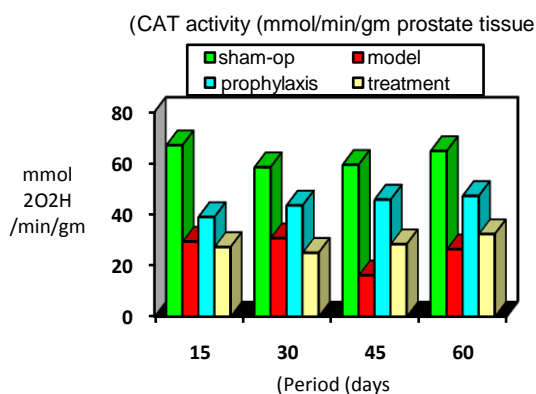


Fig. (12) Changes in tissue CAT

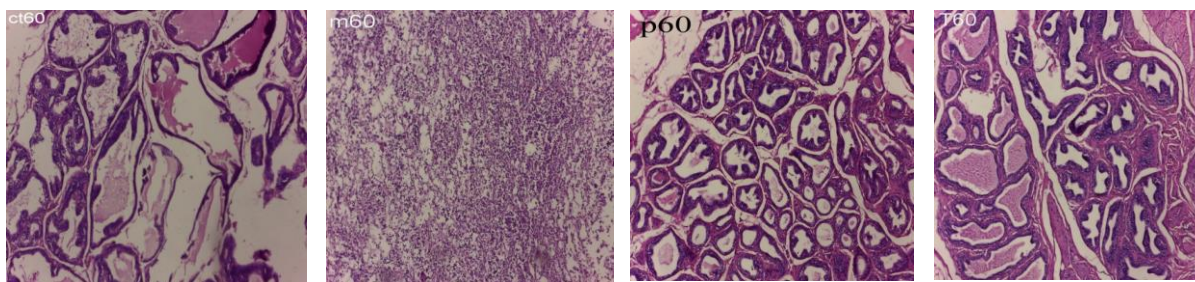


Figure (13) photomicrographs of rats prostates histology sections at 60 days, Normal glandular appearance no inflammatory cells either luminal or stroma but acini were dilated in section (ct60) for control group. Complete necrosis and destroyed tissue architectures with mixture of chronic inflammatory lymphocytic cells and severe inflammatory infiltrates mainly PMNL seen in section (M60) for model group. Increased number of acini with regular shape resemble normal sections but shrinking was still excite and no inflammatory infiltrates either stroma or lumen were seen in prophylaxis group, section (P60). Moderate lymphocytic infiltration in stroma with irregular acini structures and lumen have no inflammatory cells appear in section (T 60) for treatment group.

DISCUSSION

Our results indicated that; at 15 days from the starting point there are aggressive decline in serum testosterone concentration with three groups (model, prophylaxis, and treatment) compared with control group while serum estradiol concentration significantly increased which is corresponding to our work hence these three groups are castrated it became without testes, site of sex hormone production, while estradiol is synthesized in male reproductive system by at least three different cell types, Sertoli, Leydig and germ cells, its concentration increased because we supplied these groups with exogenous high dose estradiol by daily s.c injection (**Hassan et. al, 2012**). Cytokines concentration in serum (PGE2, IL-8) were highly elevated with three groups (model, prophylaxis, and treatment) indicating inflammatory process take place compared with control group. For prophylaxis group there are significant decreases in inflammatory action compared to model group indicating pollen may by counteract the inflammatory process inside prostate. These findings are in agreement with that of **Cheng Yang et. al, (2014)**, **Elberry et. al. (2011)**, **Kamijo et. al, (2002)**, and **Loschen&Ebeling (1991)**. By the same manner oxidant parameters (MDA, NO) in prostate tissues elevated with three groups (model, prophylaxis, and treatment) indicating lipid peroxidation action lead to destruction of prostate cells membrane compared with normal group (**Khalil and El-Sheikh (2010)**). The action of pollen as prophylaxis is clear for MDA; however there was no effect on NO concentration through the first 15 days, since there was no significant differences between the three groups in NO concentration. Antioxidant levels (GSH concentration, GSHPx, SOD, and CAT activities) in prostate tissues were highly decreased with three groups (model, prophylaxis, and treatment) indicating suppression the ability of prostate tissues to overcome oxidation process and restrain cells architecture and function compared with control group. pollen can act as a facilitator for antioxidant mechanism as clear in prophylaxis group hence there were significant increase antioxidant action of GSH, GSHPx, and CAT compared with the other two groups (model, and treatment), while pollen has no effect on SOD action through first 15 days which compatible with findings illustrated by **Khalil and El-Sheikh (2010)** . Serum IGA concentration was significantly decreased with three groups (model, prophylaxis, and treatment) as a sign of immunosuppression action of hormonal imbalance induced in these rats by stop the production of testosterone and increase estradiol concentrations compared with control group. Pollen has no action on serum IGA concentration through the first 15 days of the study. Histopathological study showed normal glandular appearance with well defined epithelium cells lining filled with secretion and no inflammatory cells either luminal or stroma for rats in control group. While rats suffered from aggressive depleted serum testosterone and elevated serum estradiol concentrations led to shrinking acini with atrophied epithelium and severe inflammatory infiltrates were seen in lumen and stroma with model group which proved that abacterial prostatitis model-building was successful, which in accordance with the report of literatures of **Hanamoto et. al. (1998)**, and **Seethalakshmi et. al, (1996)**. Using bee pollen didn't altered steroids hormones concentration in serum for rats we studied because these rats were castrated, but its action on inflammatory cytokines and oxidative stress process is clear with prophylaxis group having mild to moderate inflammatory infiltrates mainly in stroma with acini structures resemble normal tissues, these results compatible with data illustrated With **Asakawa et. al, (2001)**.

At 30 days from the starting point, emphasis the action of pollen as anti inflammatory through inhibition of cyclooxygenase and lipooxygenase pathway to a degree of normalize serum PGE2 concentration at 30 days of daily dose 1250 mg pollen / kg body weigh which compatible with other literatures as **Maruyama1 et. al, (2010)**, **Asakawa et. al, (2001)**, and **Kamijo et. al, (2002)** . There were improvement in antioxidant action (GSH concentration, GSHPx, and CAT activities) with prophylaxis group to a degree of normalize GSH concentration in prostate tissues compared with model group when these rats administrated pollen of daily dose 1250 mg pollen / kg body weigh, while SOD action was started to significantly increase compared with the other tow groups (model, and treatment) at 30 days which agreed with **Hong-Jie et. al, (2002)**.

At 45 days from the starting point, The action of pollen as anti-inflammatory reflects on the cytokines levels (IL-8, PGE2) since their levels in prophylaxis group significantly dropped under level in normal group, while its levels normalized with treatment group which start to administrate pollen for past 15 days only, this rapid improvement compared with prophylaxis group is illustrated by stopping exogenous inflammatory agent, s.c. injection of E2, which lead to rapid decrease in serum cytokines level in treatment group. There were improvement in antioxidant action (GSH concentration, GSHPx, and CAT activities) with prophylaxis group compared with model group to a degree of normalize GSHPx level and high significant increased GSH level in prostate tissues over normal level while rats in model group suffered from more worsen in antioxidant action than other groups. As we stopped s.c. injection of E2, pollen start to act as immunoregulator through improvement in serum IgA level with prophylaxis and treatment groups but the effect was rapid with prophylaxis group which agreed with **Dudov et. al, (1994)**.

At the end of our study after 60 days from the starting point, significant decrease in inflammatory cytokines with prophylaxis and treatment groups compared with control group emphasis the action of pollen as cyclooxygenase and lipooxygenase inhibitor. There are rapid overcome of oxidation process with pollen treatment when it used as a prophylaxis more than late treatment. Androgen depletion accompanied with estrogen elevation in male may lead to

disturbance in immune system, pollen can regulate this action hence IgA level reached to normal level within 30 day after stop estrogen injection for rats protected with bee pollen (1250 mg/kg.bw) as a prophylaxis for a total period of 60 days starting from the first day of estradiol injection as illustrated by above, which may reflect on symptomatic improvement as found by **Tommaso et. al, (2014)**.

After the end of study histopathological finding in figure (12) showed Increasing numbers of acini with regular shape resemble normal sections but shrinking was stilling excite and no inflammatory infiltrates either stroma or lumen were seen in prophylaxis group sections (P60) which is compatible with **Hanamoto et. al. (1998)** and **Kamijo et. al, (2002)**.

Conclusion:

Finally we successfully established rats abacterial prostatitis model-building by castration followed by sex-hormone-imbalance. Prostatitis was identified by histopathological study and elevated levels of serum estradiol, serum PGE2, serum IL-8, MDA, and NO concentrations in prostate tissues, accompanied with dropped levels of GSH concentration, GSHPx, SOD and CAT enzymes activities in prostate tissues. In addition to immunosuppression action characterized by low serum level of IgA. Bee pollen suspension with a dose of 1250mg/kg b.o. have a biochemical effects to improve rats abacterial prostatitis through decreasing PGE2, IL-8, MDA, and NO levels, accompanied with increasing GSH levels, GSHPx, SOD, and CAT activities. In addition to regulate immune response by normalize IgA level. We found that, using Bee pollen suspension with the mentioned dose as prophylaxis can improve inflammation, oxidative stress, and restore function and structure of prostate cells more rapidly than late treatment. So we advice men over 50 years old to daily administrate pollen as prophylaxis of prostatitis and restore prostate cells structure and function.

Acknowledgement:

Special thanks for centre of excellence in scientific research (CESR) that follow faculty of Veterinary Medicine – Banha University, especially Prof. Dr. Afaf Desoky Abd El-Magied the executive manager of the project. That funded by management supporting excellence (MSE) and Banha University.

REFERENCES:

- Akdere, H.; Oztekin, I.; Arda, E.; Aktoz, T.; Turan, F. N.; Burgazli, K. M. (2015).** Analgesic Effects of Oligonol, Acupuncture and Quantum Light Therapy on Chronic Nonbacterial Prostatitis. *Iran Red Crescent Med J*; 17(4): e26006.
- Asakawa, K.; Nandachi, N.; Satoh, S.; Honma, M.; Namikata, S.; Ishii, M.; Yasumoto, R.; Nishisaka, N.; Masuda, C.; kishimoto, T. (2001).** Effects of cernitin pollen-extract (Cernilton) on inflammatory cytokines in sex-hormone-induced nonbacterial prostatitis rats . *Hinyokika Kiyō*; 47(7):459-65.
- Beutler, E.; Duron, O.; Kelly, B. M. (1963).** Improved method for the determination of improved method for the determination of blood glutathione. *J. Lab. Clin. Med.* 61:882-888.
- Cai, T.; Wagenlehner, F. M. E.; Luciani, L. G.; Tiscione, D.; Malossini, G.; Verze, P.; Mirone, V.; Bartoletti, R. (2014).** Pollen extract in association with vitamins provides early pain relief in patients affected by chronic prostatitis/chronic pelvic pain syndrome. *Experimental and Therapeutic Medicine*, 8, (4):1032-1038
- Dudov, IA.; Morenets, AA.; Artiukh, VP.; Starodub, NF. (1994).** Immunomodulatory effect of honeybee flower pollen load. *Ukrainskii Biokhimicheskii Zhurnal*, 66(6):91-93.
- Elberry, A. A.; Mufti, S. T.; Al-Maghrabi, J. A.; Abdel-Sattar, E. A.; Ashour, O. M.; Ghareib, S. A.; and Mosli, H. A. (2011).** Anti-inflammatory and antiproliferative activities of date palm pollen (*Phoenix dactylifera*) on experimentally-induced atypical prostatic hyperplasia in rats. *Journal of Inflammation*; 8:40.
- Esterbauer, H.; Cheeseman, KH.; Dianzani, MU.; Poli, G.; Slater, TF. (1982).** Separation and characterization of the aldehydic products of lipid peroxidation stimulated by ADP-Fe²⁺ in rat liver microsomes. *Biochem Journal*; 208:129-140.

- Hanamoto, M.; Liao, M.; Suzuki, H.; Ohba, M.; Honma, Ma.; Nagashima, A.; Namikata, S.; Satoh, Sh.; Ishii, M.; Kimura, F.; and Higaki, E.** (1998). Effect of Cernitin™ pollen-extract on the Sex-hormone-induced Nonbacterial Prostatitis in Rats. *Jpn.Pharmacol. Ther*; 11:65.
- Hassan, W. A.; El-kashlan, A. M.; and Ehssan, N. A.** (2012). Egyptian Date Palm Pollen Ameliorates Testicular Dysfunction Induced by Cadmium Chloride in Adult Male Rats. *Journal of American Science*; 8(4):659-669.
- Hong-Jie, Ch.; Zhi-Ping, W.; Yi-Rong, Ch.; Da-Shan, Q.; Sheng-Jun, Fu; Mabao-Liang** (2002). Effects of pollen extract EA-10, P5 on chronic prostatitis or infertility with chronic prostatitis. *Acta Pharmaco Sin*; 23 (11):1035-1039 .
- Jung, Y. S.; Cho, Y. H.; and Han, Ch. H.** (2014). Anti-Inflammatory Effect of Phlorotannin on Chronic Nonbacterial Prostatitis in a Rat Model *Korean J Urogenit Tract Infect Inflamm*, 9(2):86-92. English.
- Kamijo, T.; Sato, S.; Kitamura, T.** (2001) Effect of Cernitin Pollen Extract on Experimental Nonbacterial Prostatitis in Rats . Toshiyuki Kamijo, Shiegeru Sato, and Tadaichi Kitamura1 *Prostate*. Oct 1; 49(2):122-131.
- Khalil, F. A.; and El-Sheikh, N. M.** (2010). The Effects of Dietary Egyptian Propolis and Bee Pollen Supplementation against Toxicity if Sodium Fluoride in Rats . *Journal of Amesrican Science*; 6(11):310-316.
- Kim, D. S.; Lee, E. J.; Cho, K. S.; Yoon, S. J.; Lee, Y. H.; and Hong, S. J** (2009). Preventive Effects of Oligomerized Polyphenol on Estradiol-Induced Prostatitis in Rats. *Yonsei Med J*. 30; 50(3): 391-8.
- Kroyer, G. and Hegedus, N. (2001).** Evaluation of bioactive properties of pollen extracts as functional dietary food supplement . *Innovative Food Science & Emerging Technologies Volume 2; Issue 3:171–174*
- Loschen, G. and Ebeling, L**(1991). Inhibition of the Arachidonic Acid Metabolism by cascade by extract of rye pollen . *Arzneim.-Forsch. (lang: ger) /Drug Res*;41 (1), Nr. 2:162-167.
- Marinese, D.; Patel, R.; Walden, PD.** (2003). Mechanistic investigation of the adrenergic induction of ventral prostate hyperplasia in mice. *Prostate*. 15;54(3):230-7.
- Maruyama, H.; Sakamoto, T.; Araki, Y.; and Hara, H.** (2010). Anti-inflammatory effect of bee pollen ethanol extract from *Cistus* sp. of Spanish on carrageenan-induced rat hind paw edema . *BMC Complementary and Alternative Medicine*;10:30
- Matsumoto, S.; Kawai, Y.; Oka, M.; Oyama, T.; Hashizume, K.; Wada, N.; Hori, J. I.; Tamaki, G.; Kita, M.; Iwata, T.; Kakizaki, H.** (2013). Bladder function in 17B- estradiol-induced nonbacterial prostatitis model in Wister rat .*Int. Urol. Nephrol.* 45(3):749-54.
- Montgomery, H.A.C.; and Dymock, J.F.** (1961). The determination of nitrite in water. *Analyst*;86: 414-416
- Motrich, R. D.; Maccioni, M.; Riera, C. M.; Rivero, V. E.** (2007). Autoimmune Prostatitis: State of the Art . *Scandinavian Journal of Immunology*; 66:217-227.
- Naslund, MJ.; Strandberg, JD.; Coffey, DS.**(1988). The role of androgens and estrogens in the pathogenesis of experimental nonbacterial prostatitis. *The Journal of Urology*, 140(5):1049-1053 .
- Nickel, J. C.; Olson, M. E.; Barbas, A.; Benediktsson, H.; Dasgupta, M. K.; and Costerton, J. W.** (1990). Pathogenesis of Chronic Bacterial Prostatitis in an Animal Model. *British Journal of Urology*, 66:41-54
- Nishikimi, M.; Rao, N.A.; Yagi, K.** (1972). The occurrence of super oxide anion in the reaction of reduced Phenazine methosulphate and molecular oxygen. *Biochem. Biophys. Res. Commun*;46, 849-853

- Paglia, D. E.; and Valentine, W. N.**(1967). Studies on the quantitative and qualitative characterization of erythrocyte glutathione peroxidase. *J. Lab. Clin. Med.* 70:158-69
- Sandford, NL.; Searle, JW.; Kerr, JF.**(1984). Successive waves of apoptosis in the rat prostate after repeated withdrawal of testosterone stimulation.*Pathology.* 16(4):406-10.
- Seethalakshmi, L.; Bala, R. S.; Malhotra, R. K.; Ritchie, T. Au.; Graziano, C. Mi.; Menon, M.; Narod, J. L.**(1996). 17 beta-Estradiol Induced Prostatitis in the Rat is an Autoimmune Disease . *J Urol.* ; 156(5):1838-42.
- Shoskes, D. A. (2002).** Phytotherapy and other alternative forms of care for the patient with prostatitis *J. Current Urology Reports*;3(4):330-334
- Sinha, AK.**(1972). Colorimetric assay of catalase. *Anal Biochem.* Jun;47(2):389-94.
- Solujic, S.; Sukdolak, S.; Vukovic, N.; Niciforovic, N.; Stanic, S. (2008).** Chemical composition and biological activity of the acetone extract of *Ambrosia artemisiifolia* L. pollen *J. Serb. Chem. Soc.*; 73(11):1039-1049.
- Steel, R.; Torrie, J.; and Dickey, D. (1997).** Principles and procedures of Statistics: A Biometrical Approach, 3rd ed., McGraw-Hill, New York, NY.
- Wolford, S. T.; Schroer, R. A.; Gohs, F. X.; Gallo, P. P.; Brodeck, M.; Falk, H. B.; Ruhren, R.**(1986). Reference range data base for serum chemistry and hematology values in laboratory animals. *Journal of Toxicology and Environmental Health*Volume; 18, 2:161-188
- Yang, BC; Jin, LL.; Yang, YF.; Li, K.; and Peng, DM. (2014).** Inhibitory effect of rape pollen supercritical CO₂ fluid extract against testosterone-induced benign prostatic hyperplasia in rats . *Experimental and Therapeutic Medicine*; 8: 31-37.
- Zhang, QY.; Mo, ZN.; Liu, XD. (2010).** Reducing effect of curcumin on expressions of TNF-alpha, IL-6 and IL-8 in rats with chronic nonbacterial prostatitis . (lang: chi) *Zhonghua nan ke xue* , National Journal of Andrology;16(1):84-88.